



## Thermal imaging cameras help diagnose health issues in small animals

Finnish research indicates that thermal imaging is a good method to detect pain

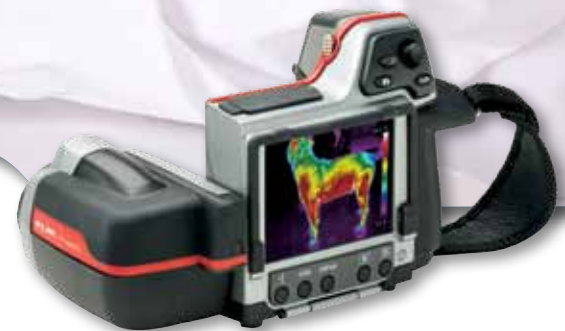*In the equestrian sports thermal imaging cameras are often used to determine and locate injuries in performance horses, but a study at the Veterinary Teaching Hospital of the University of Helsinki shows that thermal imaging cameras are a good tool to find health issues in small animals as well. "The research is not yet complete, but my initial findings are very positive", explains veterinarian and researcher Mari Vainionpää.*

*"Unlike humans animals cannot tell the doctor what they are feeling. This can make it very challenging for veterinarians to find clinical problems in animals." In thermal imaging Vainionpää has found an exciting solution. "Thermal imaging cameras really are a great tool to find out whether an animal is in pain, for instance."*

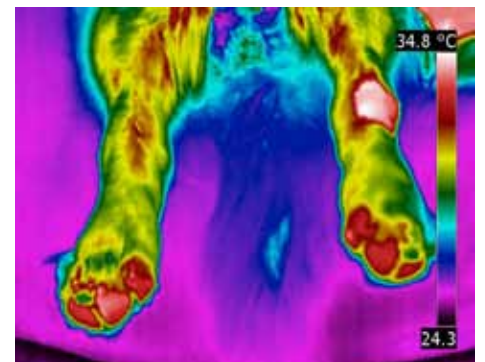
But thermal cameras can do much more. "All organic activity generates heat", continues Vainionpää. "If there are changes in the organic activity there are also changes in the amounts of heat that are emitted. These deviations in the heat pattern can be detected with a thermal imaging camera. In my experience a thermal imaging cameras can be used to reveal inflammations, bruises, tendon or muscle related injuries, superficial tumors, nerve damage, blood circulation issues."

### **Thermal imaging: quick and reliable**

According to Vainionpää a thermal imaging camera is a very useful tool for veterinary examinations. "The use of thermal imaging cameras is a quick and reliable non contact method. You don't have to sedate the animal, you don't have to touch it and using a thermal imaging camera doesn't expose the animal to potentially harmful radiation."



The FLIR T425 thermal imaging camera is smart, compact and powerful; a perfect tool for veterinary inspections.

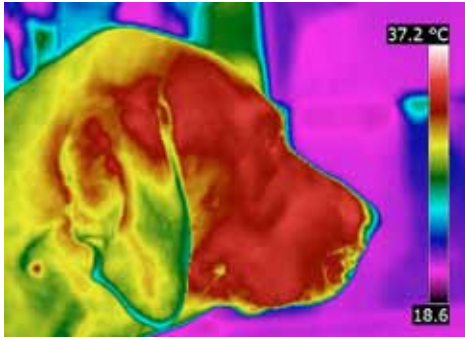


A malign tumor (to be precise: mast cell carcinoma) in the left hind leg shows up as an intense hot spot in the thermal image.

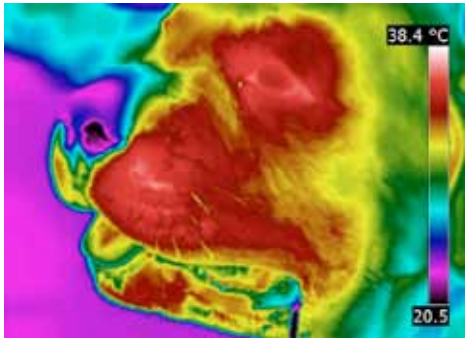


Veterinarian and researcher Mari Vainionpää.





After a viper bite on the right side of the head, close to the nose, the affected areas appear as colder spots at the puncture site due to tissue necrosis caused by the viper venom.



The decreased temperature just below the nostrils is also caused by a viper bite.

"An additional advantage of using a thermal imaging camera in relation to other diagnostic tools, such as X-ray, ultrasound and MRI scanners, is that you can immediately show the owner of the animal the initial results", continues Vainionpää. "Of course the real conclusion can only be drawn after proper analysis of the thermal image and thermal data, alongside thorough clinical examination, but I have received some very positive feedback from pet owners about the fact that they could immediately see some

initial results. Thermal imaging cameras are very intuitive and that makes it a lot easier for the pet's owners to understand exactly what I am trying to do."

## FLIR T425 thermal imaging camera: perfect for the job

But Vainionpää stresses that not every thermal imaging camera is suitable for this purpose. "I have compared several cameras and I came to the conclusion that the T425 is the best thermal imaging camera at the moment for my purposes, for in my experience you probably need a resolution of at least 320 x 240 pixels and a sensitivity of less than 50 mK to be able to see the small anomalies in the thermal pattern that you need for diagnosing health problems in small animals."

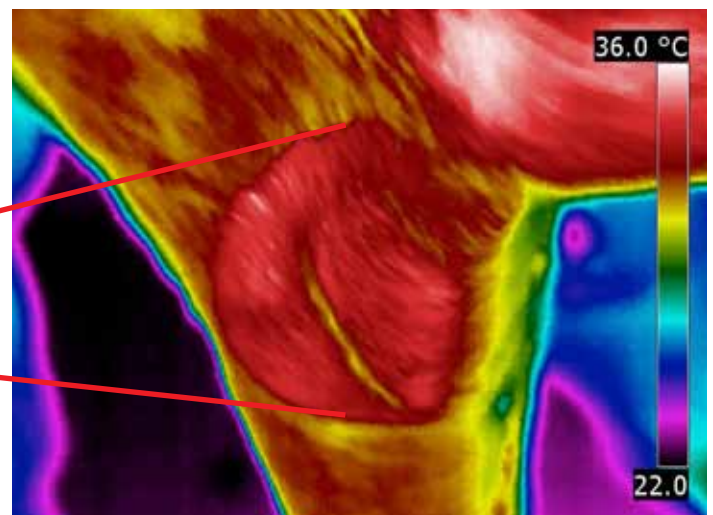
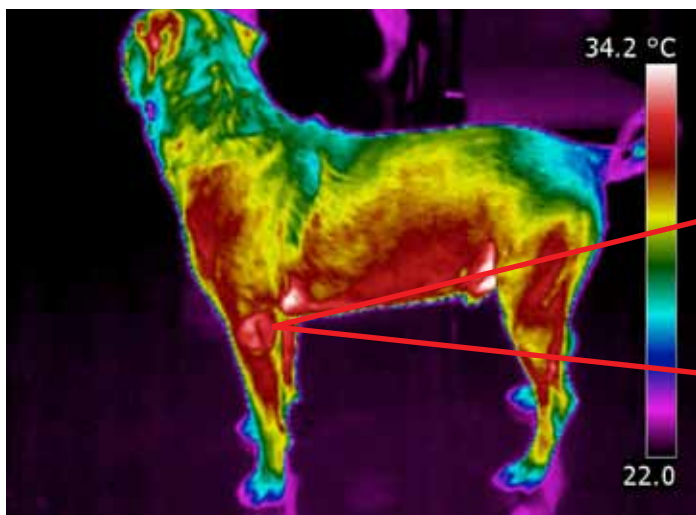
The FLIR T425 thermal imaging camera that Vainionpää uses for her work as a veterinarian at the Veterinary Teaching Hospital in Helsinki takes ergonomics, weight and ease-of-use to a new level. Usability is key: the engineers at FLIR Systems have translated user feedback on comfort and clarity into a series of comprehensive and innovative features. The tiltable lens unit is especially useful, according to Vainionpää. "That allows me to easily take thermal images from every possible angle and still see what I'm doing on the screen. Combined with the fact that it is very compact and lightweight this makes the FLIR T425 thermal imaging camera the perfect thermal imaging camera for this application."

## Breakthrough


Vainionpää is very positive about the added functionality thermal imaging cameras have for veterinarians. "In my experience thermal imaging cameras can sometimes even lead to a breakthrough. There was one case for instance of a dog that had been lame for years and even with x-ray, CT or MRI scans the vets had not been able to find out what the problem was. One of my colleagues asked me to take a look with my thermal imaging camera and I was able to locate the problem in the front left elbow. Based on that information my



Vainionpää is very pleased with the ergonomic design of the FLIR T425 thermal imaging camera. "The fact that it's light and compact makes it a perfect tool for a veterinarian."



The dog in these pictures has had lameness for several years. The origin couldn't be specified by x-ray, CT or MRI scans. With the help of the thermal imaging camera the problem was localized to the elbow.



These thermal images that were taken with a T200 (resolution 200 x 150 pixels) during earlier tests, clearly show that initially the bandage is too tight, which causes loss of blood circulation. The thermal image on the right shows loosening the bandage has restored the blood flow.

colleague could continue the investigation and following treatment.”

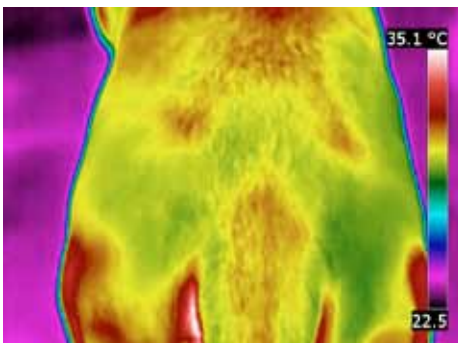
Vainionpää stresses that she doesn't mean to say that thermal imaging cameras would make other diagnostic methods obsolete. “For certain conditions scans with X-ray, ultrasound and MRI devices are still necessary and I'd also like to stress that using a thermal imaging camera cannot replace physical examinations, but in my experience the thermal imaging camera is an extremely useful addition to the existing arsenal of diagnostic equipment.”

### Very affordable

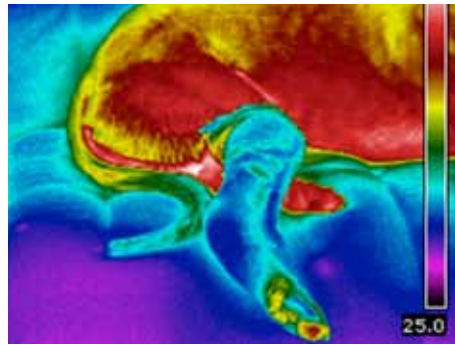
According to Vainionpää the price tag of a thermal imaging camera shouldn't be a big obstacle. “If you compare the price of a thermal imaging camera with the price tags on other diagnostic tools like X-ray, ultrasound and MRI scanners then thermal imaging cameras really are very affordable in comparison. In my opinion that makes a thermal imaging camera a very good investment.”

### Detecting pain with thermal imaging

One of the main purposes for which Vainionpää uses the thermal imaging camera is to determine whether the animal is in pain



This dog has been hit by a car. The thermal image shows a cold area in the right pelvic area because the dog bears less weight on the right hind limb.



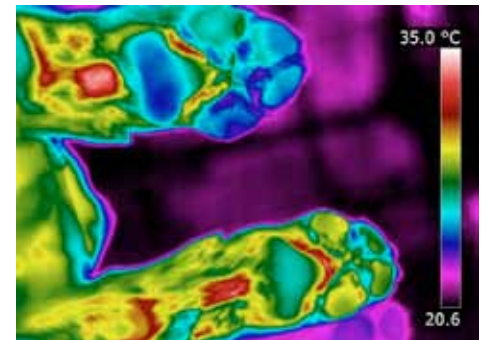
and where the origin of that pain is located. “Finding out if the animal feels pain can sometimes be a real challenge for a vet. Most animals will try to hide their weakness and will only show that they're in pain when the pain has become unbearable. So a common method to determine whether an animal is in pain consists of touching the animal in the area where pain is suspected and monitoring the animal's response closely. This is, however, not always reliable, for the animal might be very determined not to show signs of pain and another consideration is that the owner of the animal often doesn't like the fact that the veterinarian is causing more pain to their beloved animal. Thermal imaging cameras can provide an interesting solution to that problem, for it does not involve touching the animal and it can be used to show anomalies in the thermal pattern.”

But according to Vainionpää the operator has to be very careful not to draw false conclusions. “Let's take a typical example: a dog with a painful limb. If the thermal image shows that one leg is warmer than the rest that might indicate that the hot leg is injured and the increased blood flow in the damaged tissue causes the rise in temperature. The injured leg might also be the diagonally opposite or adjacent one, however. It might be using the injured leg less, because of the pain, which means that the opposite leg is used more. In that case the increased blood flow due to the intensive use of the limb caused the high temperature. So you have to know what you're doing.”

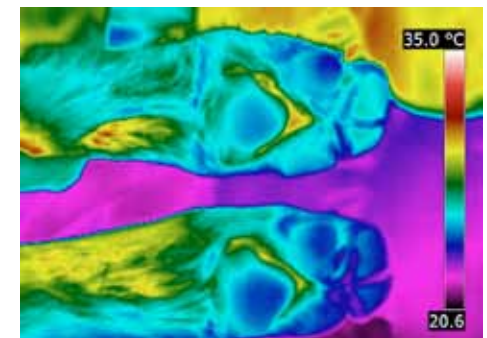
### Paw print method

Vainionpää has further developed some interesting methods for the veterinary use of thermal imaging cameras. “One of the methods I use to find out if an animal is

in pain is by using the heat residue in the floor from the animal's paws. The heat from the animal's paws is transferred to the floor surface. This lingering heat is visible on the thermal image as paw mark that stays behind after the animal walks away. Based on the temperature and location of those paw marks I can determine how the animal distributes its weight between the legs. If it's using one limb less than the other three limbs, that's an indication that the animal is in pain.”



The left front paw (the lower paw in the picture) shows up as warmer in the thermal image. It was caused by a tiny splinter embedded in the sole of the paw.



The two hind paws have similar temperatures. This picture was taken for comparison.

### Wood splinter

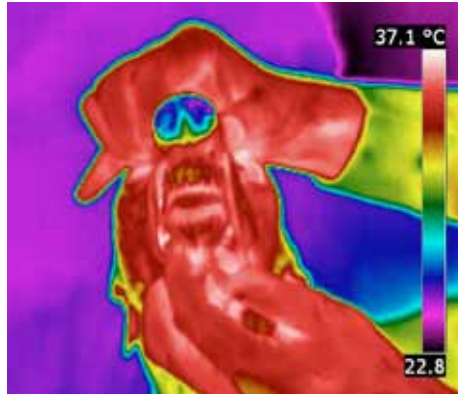
This method has led to good results in several cases, explains Vainionpää. “One of my co-workers had a dog that was limping. Orthopedic examination had failed to find the problem, so she asked me to take a look. An inspection with my thermal imaging camera revealed that the lame leg had significantly warmer sole than the other three. Since there was no obvious reason for that we took another look and found a tiny wood splinter. After removing the splinter the lameness was also gone. Without the thermal inspection, that splinter would probably have remained undiscovered for quite some time.”

## Diagnosing teeth

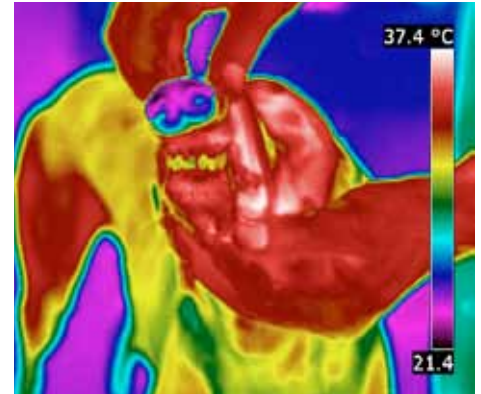
“Currently we’re also trying to find out whether thermal imaging cameras can also be used to diagnose tooth problems”, continues Vainionpää. According to Vainionpää the tooth temperature could be related to the condition of the nerve tissue inside the tooth. “It seems that teeth with healthy nerve tissue have a warmer temperature than teeth that have damaged nerve tissue. If my hypothesis is correct, comparing the temperature of teeth can help to indicate teeth health, where teeth showing up as cold spots in the thermal image will indicate nerve damage. We are now investigating whether there is a significant correlation between the condition of the nerve tissue and the tooth temperature.”

## Diagnosing osteoarthritis in elderly cats

One of the main goals Vainionpää has set herself has nothing to do with dogs, however: it is regarding cats. “I want to accurately determine whether a cat is feeling pain, for cats are even better than



The thermal image of another greyhound that has healthy teeth shows no thermal anomalies.



This thermal image shows a greyhound with bad teeth. The bad teeth show up as a cold spot.

most other animals, such as dogs, at hiding their pain. Several recent studies have shown that older cats will develop what is called ‘osteoarthritis’, a degenerative joint disease that leads to aching joints. Luckily modern veterinary science can provide pain medication that can take away most of the pain. But because the symptoms develop gradually and because cats are very good at hiding pain, most cases of

osteoarthritis in elderly cats at present remain undiscovered.”

With the help of thermal imaging cameras Vainionpää hopes to be able to better diagnose osteoarthritis in elderly cats. One example of this is Vainionpää’s own cat. “I found that my own cat had osteoarthritis using my thermal imaging camera. This happened by accident. I needed a thermal image of a cat for a presentation I was asked to give on this subject, so I thought: why not take a thermal image of my own cat? When I had taken the image and saw the result I was startled: I saw a hot spot in the right hip, which I knew might indicate pain.”

## Difficult diagnosis

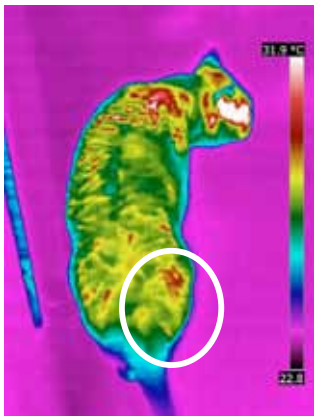
The discovery was an unpleasant surprise for Vainionpää. “Apparently

my cat had been in pain for quite some time and I had not noticed. Looking back there were some signs, he had been even crankier than usual, but it was only after I had seen the thermal image that I understood what was going on. This illustrates how difficult it is to diagnose osteoarthritis in elderly cats and why so many remain undiagnosed.”

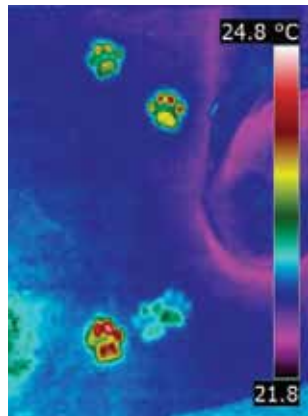
Even though the irony of this situation is quite obvious, Vainionpää is very happy that this happened. “Now that I found out about the osteoarthritis I have put my cat on the right pain medication and it seems that the symptoms have gone. Both his behavior and the regular thermal inspections show no signs of pain.”

## Alleviate unnecessary suffering

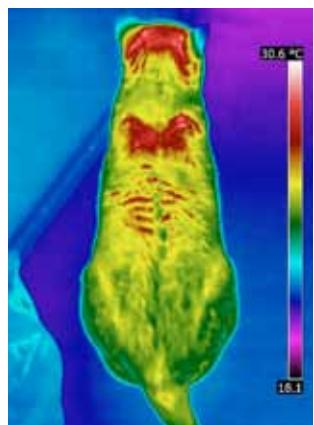
Her research into the use of thermal imaging cameras as a diagnostic tool to determine whether elderly cats have osteoarthritis is not yet complete, but her initial finding is that it improves the chance of finding the osteoarthritis significantly. “I hope that my research will prove that veterinarians can accurately determine whether a cat is in pain using a thermal imaging camera. In my opinion all veterinarians should at least consider this method, for it can help alleviate unnecessary suffering of elderly cats all over the world”, concludes Vainionpää.




This thermal image of Vainionpää’s own cat shows an increase amount of heat emitted from the right hip area, indicating a painful hip.



The paw prints show that the cat puts less weight on the right hind limb and more weight on the left hind limb and front right limb to compensate.



This thermal image of the same cat after receiving proper pain medication shows no thermal anomalies in the painful hip area.



After proper pain medication the cat’s weight is evenly distributed between all four limbs.

For more information about thermal imaging cameras or about this application, please contact:

FLIR Commercial Systems B.V.  
Charles Petitweg 21  
4847 NW Breda - Netherlands  
Phone : +31 (0) 765 79 41 94  
Fax : +31 (0) 765 79 41 99  
e-mail : flir@flir.com  
www.flir.com